






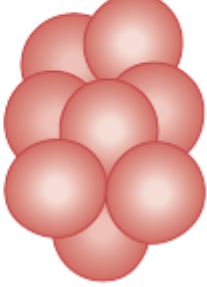






















Red Blood Cell Observations

RBC : disk-like shape, Often called a biconcave disk. Normal mature RBCs, have no nucleus, and are 6 to 8 µm in diameter

Anisocytosis

The condition in which markedly different sizes of RBCs are present is called **Anisocytosis**

- 1- **normocytic** (normal) RBC 6 to 8 µm in diameter
- 2- **microcytic** , RBCs that are smaller than 6 µm
- 3- **macrocytic** , are larger than 8 µm

RED BLOOD CELL MORPHOLOGY					
Size variation	Hemoglobin distribution	Shape variation		Inclusions	Red cell distribution
Normal 	Hypochromia 1+ 	Target cell 	Acanthocyte 	Pappenheimer bodies (siderotic granules) 	Agglutination 
Microcyte 	2+ 	Spherocyte 	Helmet cell (fragmented cell) 	Cabot's ring 	Rouleaux 
Macrocyte 	3+ 	Ovalocyte 	Schistocyte (fragmented cell) 	Basophilic stippling (coarse) 	
Oval macrocyte 	4+ 	Stomatocyte 	Tear drop 	Howell-Jolly 	
Hypochromic macrocyte 	Polychromasia (Reticulocyte) 	Sickle cell 	Burr cell 	Crystal formation HbSC  HbC 	

Hemoglobin distribution :

- 1- RBCs with the normal amount of hemoglobin are called **normochromic**. These cells stain evenly, with only a small pale area in the center of the cells.
- 2- A **hypochromic** RBC has less than the normal amount of hemoglobin, with only a ring of hemoglobin around the cell's outer edge and a large central pale area.
- 2- A **hyperchromic** RBC has more than the normal amount of hemoglobin

Normal production and development of RBCs require certain factors such as vitamins and minerals. Iron deficiency is one cause of microcytic, hypochromic RBCs. Deficiencies of vitamins such as B12 and folic acid cause the cells to be macrocytic.

TABLE 2-14. Examples of conditions that affect red blood cell morphology

CELL MORPHOLOGY	CONDITIONS
Size	
Normocytic	Normal
Microcytic	Iron deficiency anemia, thalassemias
Macrocytic	Vitamin B ₁₂ deficiency, folate deficiency
Shape	
Round, biconcave disk	Normal
Sickle	Sickle cell disease
Spherical	Hereditary spherocytosis
Hemoglobin Content	
Normochromic	Normal
Hypochromic	Iron deficiency anemia
Hyperchromic	Spherocytosis

Poikilocytosis

Poikilocytosis, variation in the shape of RBCs, can be inherited (have a genetic cause) or acquired

1- Sickle Cells: Drepanocytes

Sickle cell disease is an inherited condition in which Hb-S causes the RBCs to have a characteristic *sickle* shape when oxygen levels are decreased

2- Spherocytes

Spherocytes are RBCs that are spherical instead of the normal biconcave shape.

3- Elliptocytes

Elliptocytes are elongated, cigar-shaped RBCs

4- Stomatocytes

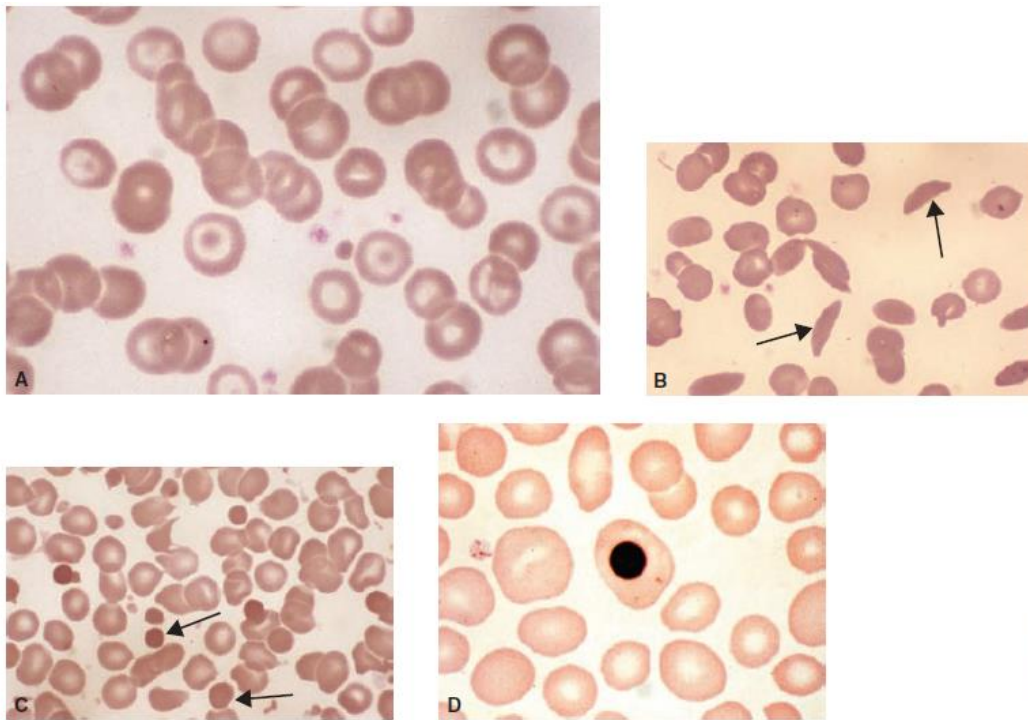
RBCs with a linear area of pallor are called **stomatocytes** because the pale area is shaped like a mouth.

5- Target Cells: Codocytes

Target cells are red blood cells that resemble a bull's eye target; they are also known as **codocytes**. Target cells can be seen in thalassemia, sickle cell disease, and other hemoglobin abnormalities

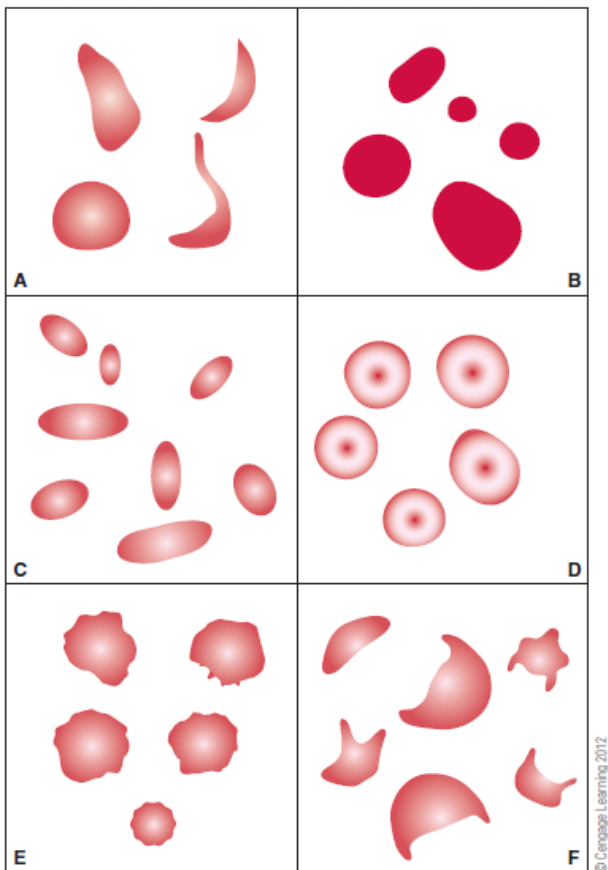
6- Keratocytes: Schizocytes

Fragmented RBCs are called either **keratocytes** or **schizocytes**.



© Cengage Learning 2012

FIGURE 2-72 Abnormal red blood cell morphology: (A) target cells and hypochromic microcytes; (B) sickle-shaped cells in smear from patient with sickle cell anemia; (C) spherocytes and schizocytes in smear from burn patient; and (D) nucleated red blood cell



© Cengage Learning 2012

FIGURE 2-73 Morphology of selected abnormal red blood cells: (A) drepanocytes (sickle cells); (B) spherocytes; (C) ellipocytes; (D) codocytes (target cells); (E) crenated cells; and (F) keratocytes including helmet cells